

Patient #: NP3183
Age: 79 M
Diagnosis: Dermal Ulcer – right heel

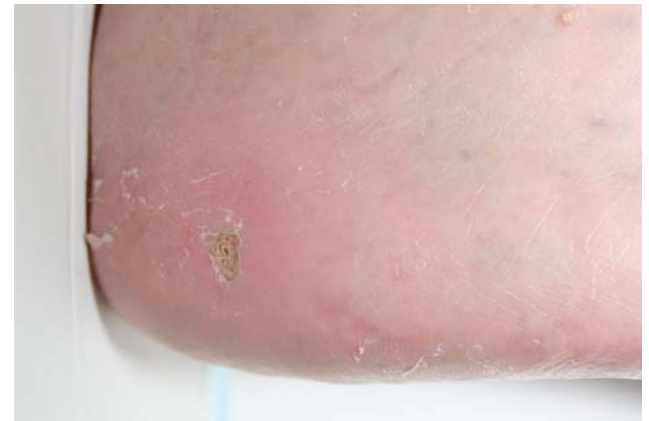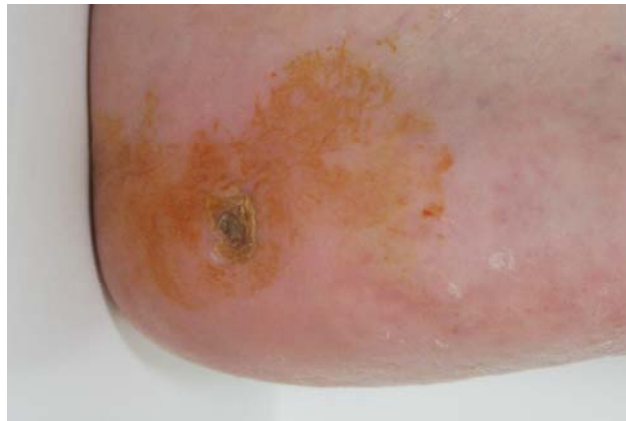
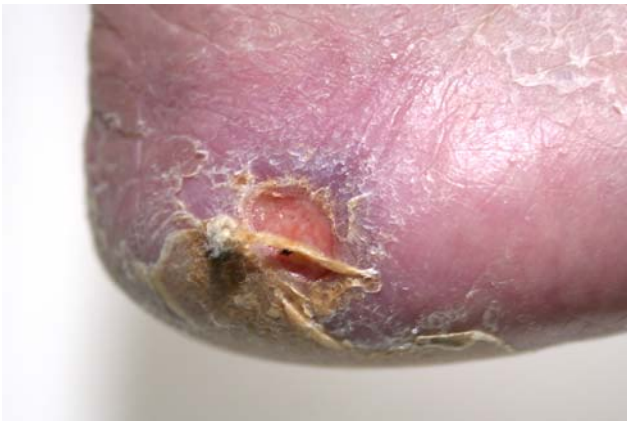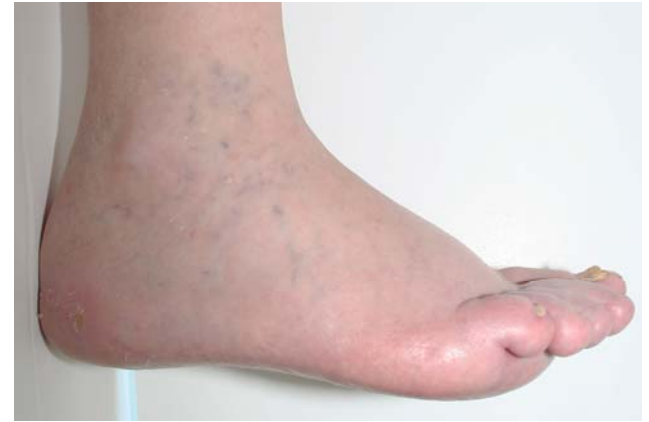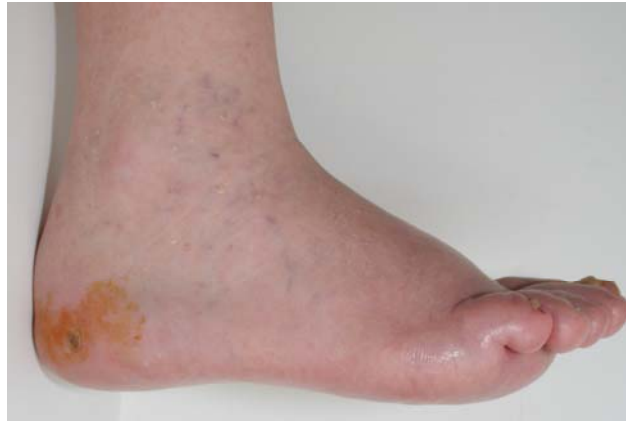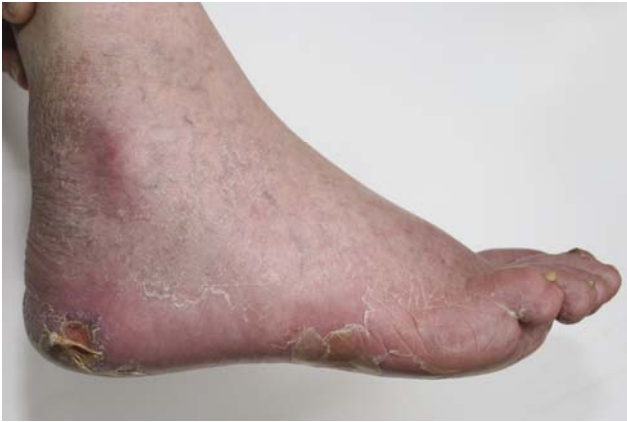CONFIDENTIAL
for medical record use



Initial

Intermediate

Most Recent



05/07/2008

07/18/2008

08/01/2008

Patient #: AH4840

Age: 72 F

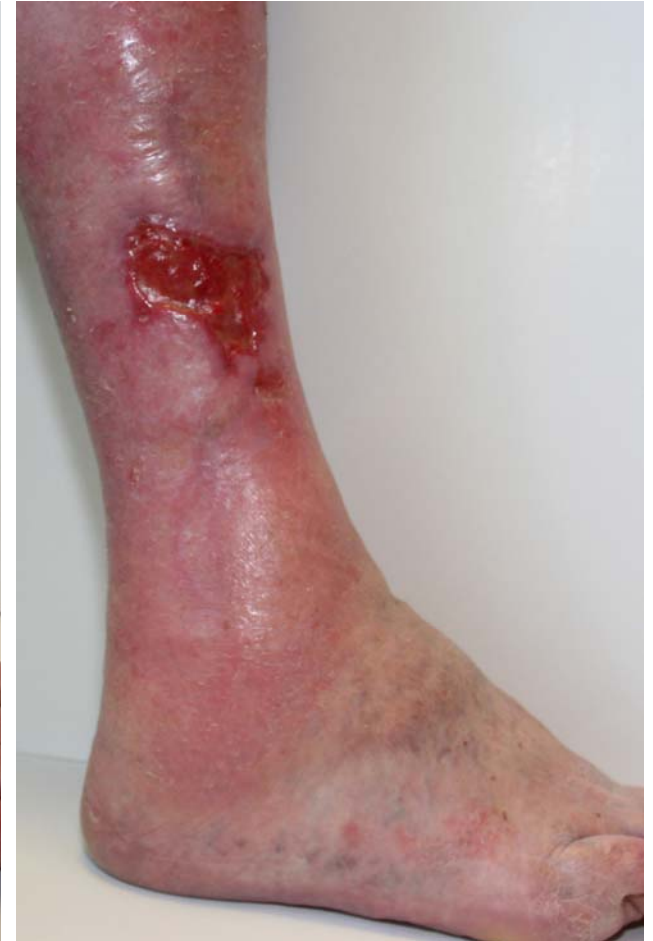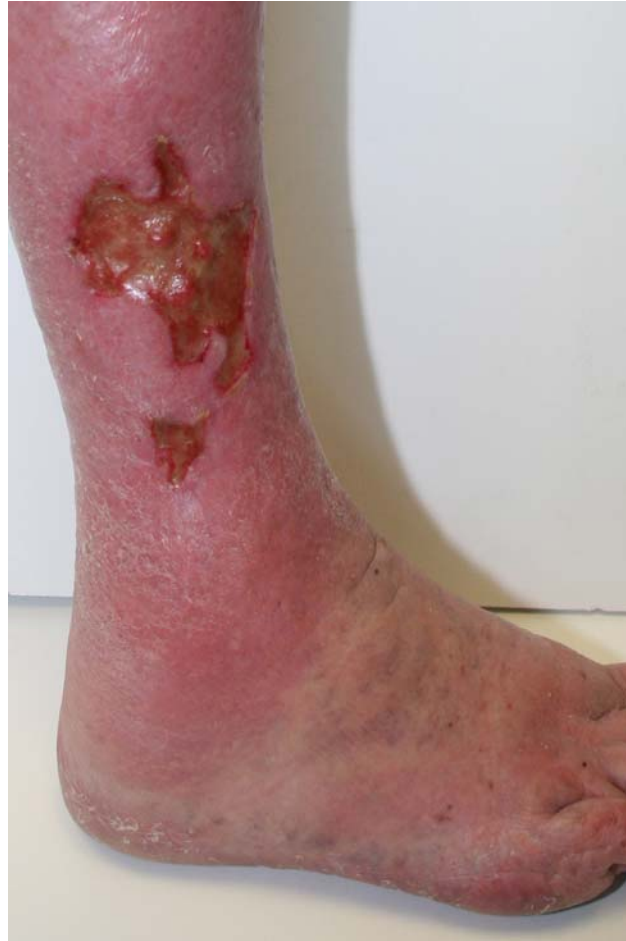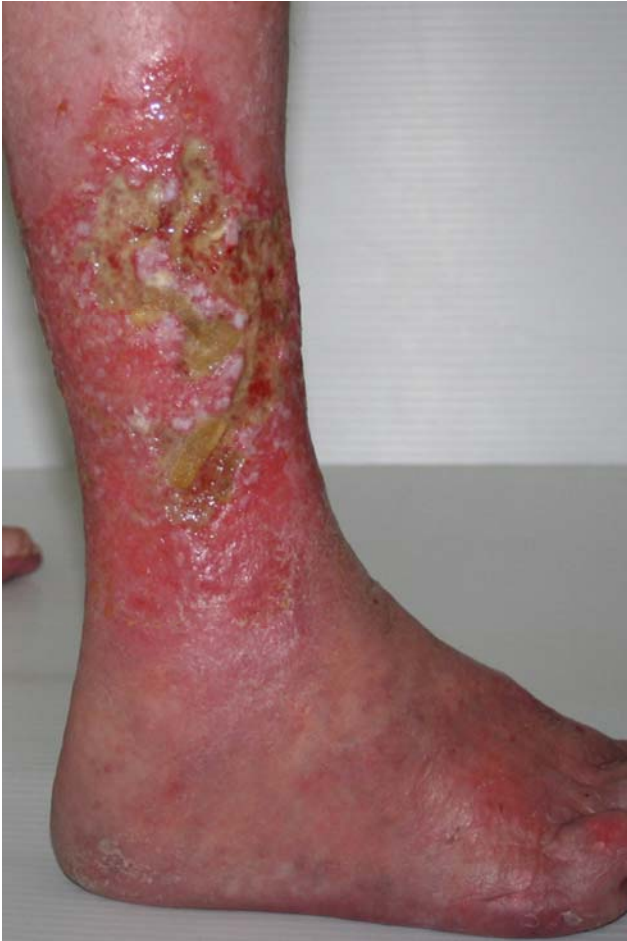Diagnosis: Infected Ulcer, secondary to inadequate arterial circulation

CONFIDENTIAL 
for medical record use

Initial

Intermediate

Most Recent



11/28/2006

Area: 111 cm²

09/10/2007

Area: 25.9 cm²

09/19/2008

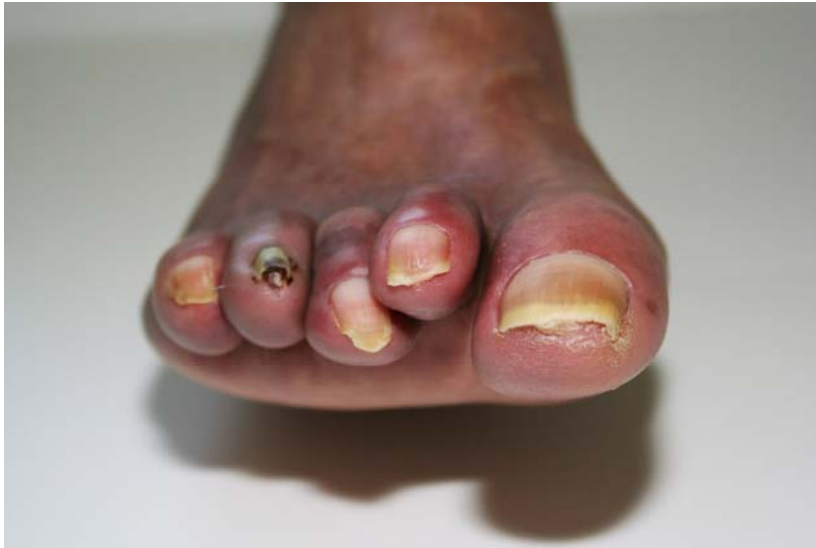Area: 7.87 cm²

Patient #: JM6332
Age: 66 M
Diagnosis: right foot

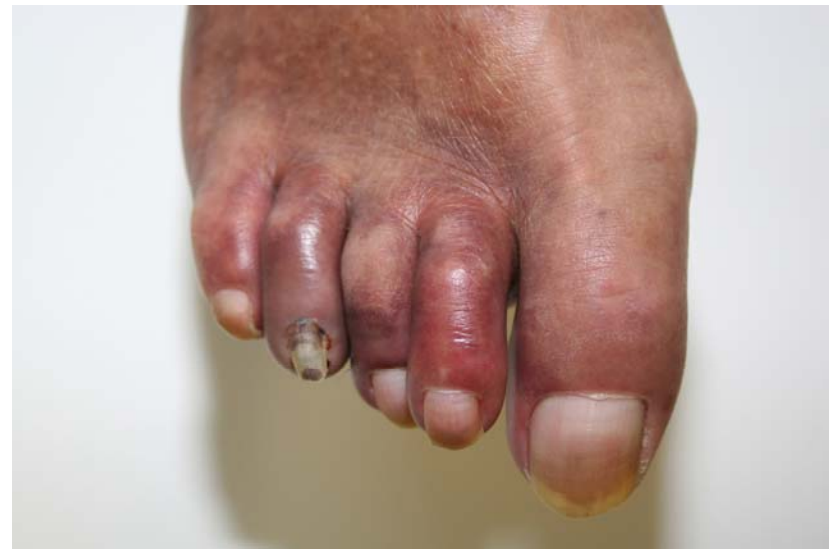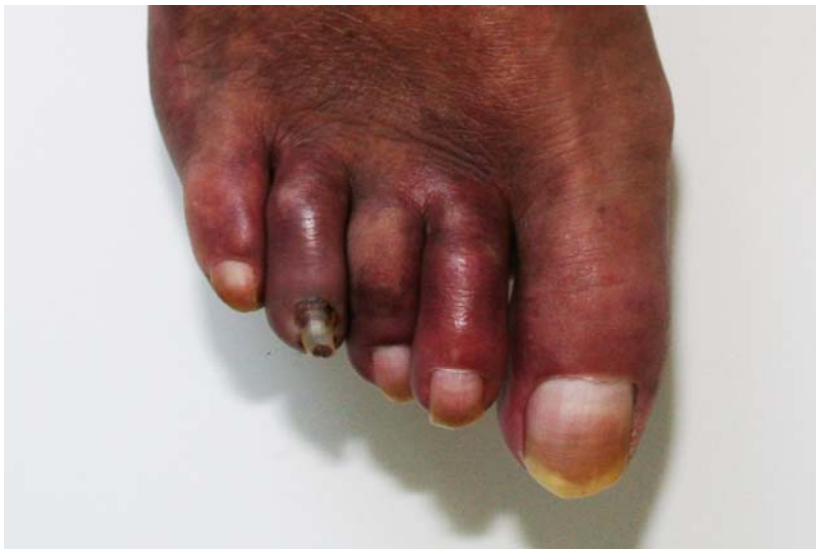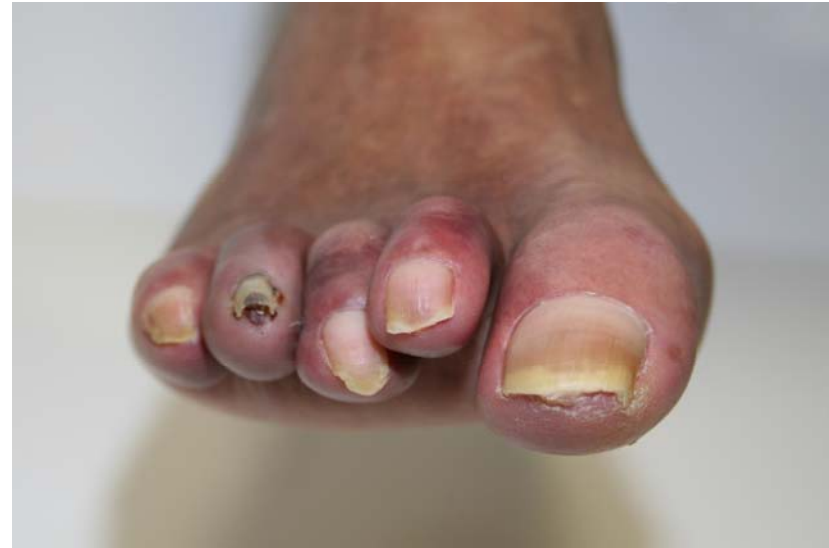CONFIDENTIAL
for medical record use



Initial



After 1 Treatments



09/10/2008

09/12/2008